



Laryngeal schwannoma – A case report with short literature review

Švanom larinksa – prikaz slučaja sa kratkim pregledom literature

Nenad Relić*, Milica Jevtić**†, Branislav Belić**†, Dušica Petrović Rodić‡,
Andra Jevtović**†, Natalija Božović**†, Marina Jovanović**†, Jasmina Stojanović**†

Clinical Centre Kragujevac, *Clinic for Otorhinolaryngology, ‡Department of Pathology, Kragujevac, Serbia; †University of Kragujevac, Faculty of Medical Sciences, Kragujevac, Department of Otorhinolaryngology, Kragujevac, Serbia

Abstract

Introduction. Laryngeal schwannomas are rare benign neurogenic tumors. They are usually localized in the supraglottic portion of the larynx. We reported a rare case of laryngeal schwannoma with a focus on clinical presentation, diagnosis and management. **Case report.** A 61-year old male patient with a 3-year history of hoarseness underwent telescopic examination which revealed an oval submucosal tumefaction of the left ventricular fold extending over the left vocal fold toward the right ventricular fold. Multislice computed tomography showed a 22 x 15 mm well defined, oval heterodense mass in the region of the left ventricular fold, extending toward the left vocal fold and the posterior commissure of the larynx, with signs of initial compression lesion of the thyroid cartilage. Biopsy and histopathology revealed a primary benign encapsulated mesenchymal tumor, while immunohistochemistry analysis confirmed schwannoma diagnosis. The patient underwent tracheotomy and left hemilaryngectomy, with complete removal of the tumor. There were no signs of recurrence at the six-month follow-up. **Conclusion.** Schwannomas are rare among benign tumors of the larynx and might grow for years before being diagnosed. Biopsy with histopathology analysis is used to confirm the diagnosis of laryngeal schwannoma, although extreme care should be taken during biopsy. Treatment consists of complete surgical excision; the surgical approach depends on the size and localization of the tumor, as well as on the presence of a peduncle.

Key words:

diagnosis; laryngeal neoplasms; multidetector computed tomography; neurilemmoma; otorhinolaryngologic surgical procedures.

Apstrakt

Uvod. Švanomi larinksa su retki benigni neurogeni tumori. Najčešće su lokalizovani u supraglotičnom delu larinksa. Prikazan je redak slučaj laringealnog švanoma sa fokusom na kliničkoj slici, dijagnozi i lečenju. **Prikaz bolesnika.** Muškarac, star 61 godinu, zbog promuklosti predhodne tri godine javio se na teleskopski pregled. Tom prilikom mu je otkriven ovalni submukozni izraštaj na levom ventrikularnom naboru koji se pružao preko leve glasnice ka desnom ventrikularnom naboru. Multislijsna kompjuterizovana tomografija larinksa i vrata sa kontrastom pokazala je ovalnu, heterodenznu, jasno ograničenu promenu veličine oko 22 x 15 mm u regiji levog ventrikularnog nabora koja se širila ka levoj glasnici i zadnjoj komisuri larinksa, sa znacima početne uzure tireoidne hrskavice. Biopsija i histopatološki nalaz otkrili su primarni benigni inkapsulirani mezenhimni tumor, dok je imunohistohemijska analiza potvrdila dijagnozu švanoma. Bolesniku je urađena hirurška traheotomija i levostrana hemilaringektomija, sa potpunim uklanjanjem tumora. U toku šestomesečnog postoperativnog praćenja nije uočeno prisustvo recidiva bolesti. **Zaključak.** Među benignim tumorima larinksa švanomi su retki, a mogu rasti godinama pre postavljanja dijagnoze. Biopsija sa histopatološkom analizom potvrđuje dijagnozu laringealnog švanoma, mada je neophodan poseban oprez tokom biopsije. Lečenje podrazumeva kompletnu hiruršku eksciziju, a sam hirurški pristup zavisi od veličine i lokalizacije tumora, kao i od prisustva peteljke.

Ključne reči:

dijagnoza; larinks, neoplazme; tomografija, kompjuterizovana, multidetektorska; švanom; hirurgija, otorinolaringološka, procedure.

Introduction

Schwannoma is a benign slow-growing encapsulated neurogenic tumor, originating from Schwann cells that

surround somatic and autonomic peripheral and cranial nerves, except the olfactory and optic nerves which lack Schwann cell sheath¹⁻³. Between 25% and 45% of all schwannomas are located in the head and neck area, predominantly in the

parapharyngeal space ¹. The only known risk factors for schwannoma occurrence are genetics and exposure to radiation ⁴. Laryngeal schwannomas are extremely rare and account for 0.1%–1.5% of all benign laryngeal tumors ⁵.

We presented a rare case of laryngeal schwannoma in a 61-year-old male patient.

Case report

A 61-year-old male was admitted to our clinic due to hoarseness over the past three years, which had been gradually worsening. He was a nonsmoker and consumed alcohol occasionally. Telescopic examination revealed an oval submucosal mass of the left ventricular fold extending over the left vocal fold toward the right ventricular fold (Figure 1). Laboratory and biochemical blood tests were within normal limits. We performed microlaryngoscopy and biopsy of the left ventricular fold mass. The histopathology (HP) finding showed atypical squamous cell hyperplasia with moderately edematous stroma and mild subepithelial inflammatory infiltrate. At the follow-up, we found that the left ventricular fold mass was increased in size. Multislice computed tomography showed a 22 x 15 mm well defined, oval heterodense mass in the region of the left ventricular fold, extending toward the left vocal fold and the posterior commissure of the larynx, with signs of initial lesion of the thyroid cartilage due to compression (Figure 2). After the repeated biopsy, HP finding revealed a primary encapsulated mesenchymal tumor with benign characteristics (Figure 3). Immunohistochemistry analysis showed diffuse and intensive S-100 and vimentin protein positivity, without expression of alpha-smooth muscle actin, desmin, epithelial membrane antigen, with a low proliferation index of around 1%, confirming schwannoma diagnosis. Operative treatment consisted of tracheotomy and left hemilaryngectomy, with complete removal of the encapsulated tumor. Postoperative HP report confirmed diagnosis of laryngeal schwannoma. The patient was decannulated 14 days after surgery and discharged from the hospital 16 days after surgery. There were no signs of recurrence present during the follow-up after six months.

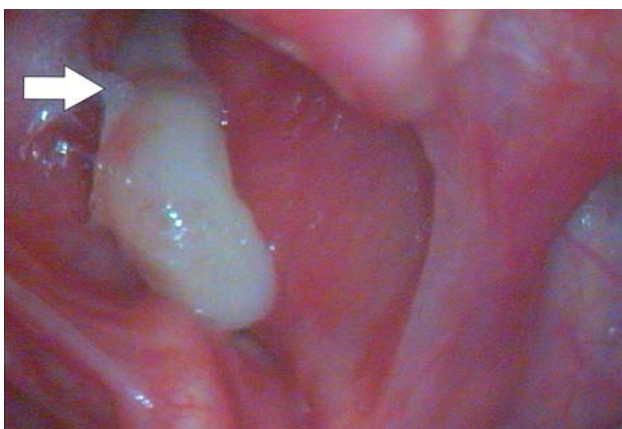


Fig. 1 – Telescopic examination showing oval submucosal mass at the left ventricular fold extending over the left vocal fold and toward the right ventricular fold (arrow showing the tumor peduncle at the left ventricular fold).

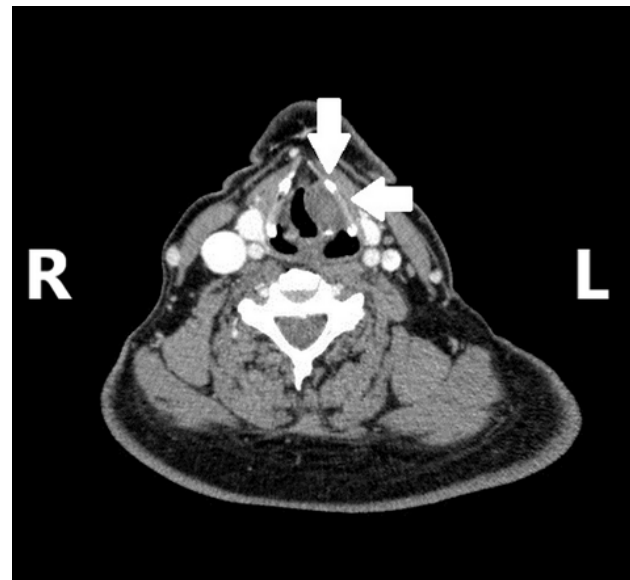


Fig. 2 – Multislice computed tomography showing an oval, well defined, heterodense mass in the region of the left ventricular fold, extending toward the left vocal fold and posterior commissure of the larynx, with signs of initial destruction of the thyroid cartilage.




Fig. 3 – Elements of a biphasic tumor, made of irregularly shaped, loosely arranged cells with hyperchromatic nuclei, immersed in the myxoid stroma, as well as bundles of elongated cells in parallel arrays, with nuclei arranged in palisade form – schwannoma (hematoxylin and eosin staining, x200).

Discussion

Laryngeal schwannomas are most common in females in the fourth and fifth decade of life, although they can occur at any age ⁶. On the contrary, our patient was a male in his seventh decade. Most commonly, the nerve of origin is the inner branch of the superior laryngeal nerve or small nerve fibers that innervate the laryngeal submucosa. In 80% of cases, laryngeal schwannomas are located at the aryepiglottic fold, while 20% occur at the vocal or ventricular fold, as in our case ².

Clinical manifestations of laryngeal schwannomas depend on their size and localization. The most common symptoms include hoarseness (71.2%), dysphagia (24.6%), dyspnea (23.3%) and globus sensation (16.4%) ⁷. Acute respiratory failure might occur, mainly in large pedunculated

tumors, which can cause complete airway obstruction⁶. A case of asphyxial death caused by laryngeal schwannoma has also been described⁸. Our patient complained of hoarseness for the past three years that had been gradually worsening. Typically, laryngeal schwannomas do not cause symptoms such as palpable cervical mass and weight loss¹, which were not present in our case either. There is only one described case of laryngeal schwannoma presenting as a painless neck mass⁹.

Differential diagnoses of schwannoma include laryngeal cyst, laryngoceles, mucocoeles, chondromas, adenomas, lipomas and neurofibromas. It is important to differentiate schwannoma from neurofibroma, because the latter have a higher incidence of malignant transformation (around 10% of cases) and a higher recurrence rate¹. The presence of neurofibroma could also indicate possible neurofibromatosis³.

Diagnosis of laryngeal schwannoma is based on anamnesis, direct or indirect laryngoscopy, imaging methods such as computed tomography and/or magnetic resonance imaging and biopsy with HP analysis¹. Ultrasonography of the larynx is rarely used, due to the difficulties in visualizing posterior structures of the tumor and the larynx. As in our case, computed tomography and magnetic resonance imaging show typical characteristics of a benign lesion: circular or oval mass with well-defined borders, mostly isodense compared to muscle and compressing without infiltrating surrounding tissue⁷. The gold standard in diagnosing schwannoma is the HP analysis². In our case histological diagnosis was based on Enger and Weiss' three histological criteria: 1) capsule presence, 2) presence of a stromal Antoni A (compacted, bipolar cells with nuclei arranged in palisade form) and/or Antoni B (loosely arranged spindle cells within a myxoid matrix) pattern and 3) positive S-100 staining⁵. However, it must be noted that incisional biopsy does not always result in correct diagnosis⁶. Results of our first biopsy showed atypical squamous cell hyperplasia instead of a schwannoma. We believe this is due to schwannoma being an encapsulated tumor and the possibility of taking superficial tumor tissue during the biopsy. This can also be explained by the lack of changes in mucosa serving as a guiding point for biopsy².

The treatment of choice for laryngeal schwannoma is complete surgical excision¹. The surgical approach primarily depends on the presence of a peduncle. Pedunculated tumors are removed endoscopically regardless of their size, while nonpedunculated tumors are treated based on their size and

localization². Small nonpedunculated tumors can be removed endoscopically, while large nonpedunculated tumors demand an open surgical approach^{1,2}. The least invasive approach should be used, while also providing the best visualization and complete tumor removal². Considering the size of the tumor and its extension toward the left vocal fold and the posterior commissure of the larynx, we opted for a left hemilaryngectomy with complete removal of the tumor. Temporary tracheostomy was conducted in order to prevent asphyxia due to possible postoperative laryngeal swelling.

The prognosis of laryngeal schwannoma is favorable. Wong et al.¹ report that 27/32 (84.38%) of patients had no signs of the disease on follow-up, while relapse occurred in 5/32 (15.62%) of patients, two of which had incompletely excised tumor. Complications caused by laryngeal schwannoma rarely occur^{3,8}, although there is a risk of postoperative recurrent laryngeal nerve paralysis¹. However, it should be noted that open surgical approaches, such as lateral thyrotomy and lateral pharyngotomy, are more frequently associated with this risk, compared to an endoscopic approach^{1,2}.

There is still no consensus on how long the patient should be monitored after the treatment. Tulli et al.⁷ report that the follow-up differs widely, from 2 months to 17 years, with laryngeal schwannoma recurrence usually being observed within 3 months after tumor excision. Therefore, controls are recommended every 3 months during the first year after excision, and then at least once a year for the next two years. We did not notice any signs of recurrence six months after surgery. We advised the patient to check in regularly, at least once a year.

Conclusion

Laryngeal schwannomas are very rare and can be overlooked for years due to their mild clinical manifestations. The gold diagnostic standard is histopathology analysis. Because of the tumor encapsulation, special care must be taken while performing a biopsy in order to avoid false-negative results. By the time the diagnosis is made, laryngeal schwannomas could significantly increase in size causing destruction of surrounding structures and consequently demand an open surgical approach. Hence, otolaryngologists should always consider schwannomas in cases of an oval or circular submucosal mass in the larynx.

R E F E R E N C E S

1. Wong BL, Bathala S, Grant D. Laryngeal schwannoma: a systematic review. *Eur Arch Otorhinolaryngol* 2017; 274(1): 25–34.
2. Markou K, Dova S, Poullos C, Karkos P. Laryngeal schwannoma as an acute airway presentation. *BMJ Case Rep* 2016; 2016:bcr2016214682.
3. Mannarini L, Morbini P, Bertino G, Gatti O, Benazzo M. Acute respiratory distress in patient with laryngeal schwannoma. *Case Rep Med* 2012; 2012: 616913.
4. Romak JJ, Neel HB 3rd, Ekblom DC. Laryngeal Schwannoma: A Case Presentation and Review of the Mayo Clinic Experience. *J Voice* 129.e15–129.e18.

5. *Chiu CC, Chou SH, Wu CC, Liang PI, Lee KW.* Obstructive laryngeal schwannoma in a young female. *World J Surg Oncol* 2015; 13: 24.
6. *Kamble BB, Deshmukh P, Methwani D, Lakhotia P.* A Rare Case of Laryngeal Schwannoma. *Ann Clin Case Rep* 2017; 2: 1364.
7. *Tulli M, Bondi S, Smart CE, Giordano L, Trimarchi M, Galli A, et al.* Diagnosis and Treatment of Laryngeal Schwannoma: A Systematic Review. *Otolaryngol Head Neck Surg* 2018; 158(2): 222–31.
8. *Gardner PM, Jentzen JM, Komorowski RA, Harb JM.* Asphyxial death caused by a laryngeal schwannoma: a case report. *J Laryngol Otol* 1997; 111(12): 1171–3.
9. *Plantet MM, Hagay C, De Maulmont C, Mabé E, Banal A, Gentile A, et al.* Laryngeal schwannomas. *Eur J Radiol* 1995; 21(1): 61–6.

Received on August 3, 2020
Revised on August 22, 2020
Accepted on August 25, 2020
Online First August, 2020